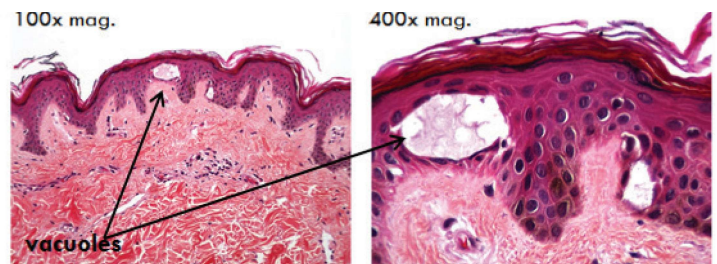


A Clinical and Histological Study of Skin Treated with a Picosecond Alexandrite Laser Using a Traditional and Fractional Lens Array

Emil A. Tangheffi, MD

Study Design:

- 18 subjects were treated with the PicoSure laser for tattoo removal 1.3-4.1 J/cm² and 5-10 Hz.
- 5 subjects also consented to have 3.5mm punch biopsies obtained at 24-48 hours post test spots on normal non-facial skin.
- Histology testing was processed with standard H&E staining.

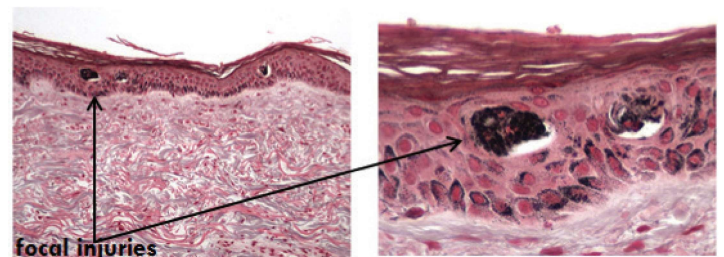


Ten minutes post:

Demonstrates vacuoles (voids) in the epidermis where optical breakdown occurred using FOCUS lens array.

Results:

- Sites treated with the straight hand piece had faint erythema at lower fluences and superficial crusting and erythema at the higher fluences 24 hours after treatment.
- Site treated with the focus array demonstrated mild erythema lasting approximately 24 hours.

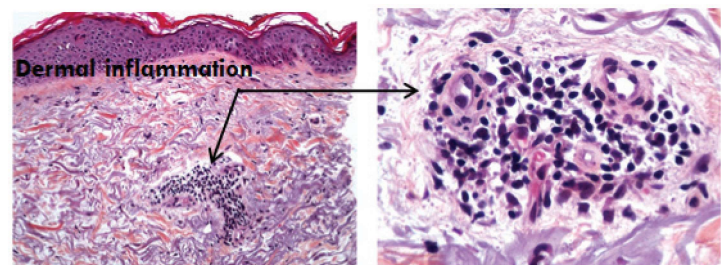


24 hours post:

Melanin staining shows focal injuries in melanin bearing cells limited to epidermis. No thermal injury noted to dermis.

Conclusion:

- Significant absorption of laser light by melanin leading to injury to collateral epidermal cells.
- The extent of injured sites appears to be both dose and pigmentation dependent as reflected by skin typing, tanning, and Melanin Index (MI).
- The diffractive lens array light delivery modality appears to selectively damage localized regions in the epidermis with a good safety and side effect profile.



24 hours post:

Standard H&E staining showing inflammatory response in dermis leading to deposition of new collagen and elastin.